

Spiders of the genus *Loxosceles* (Araneae, Sicariidae): a review of biological, medical and psychological aspects regarding envenomations

Richard S. Vetter: Department of Entomology, University of California, Riverside, California 92521; Biology Division, San Bernardino County Museum, Redlands, California 92373, USA. E-mail: rick.vetter@ucr.edu

Abstract. *Loxosceles* spiders are of concern outside of the arachnological world because their bites can cause occasional necrotic skin lesions and/or systemic complications; these manifestations are known as loxoscelism. Once these spiders became well associated as medical entities, much notoriety was attained through the publication of medical case histories as well as tales of horrific wounds in the general literature. Although most *Loxosceles* spider bites are unremarkable, require only general supportive care, and often result in excellent outcome, they are an occasional source of severe dermonecrotic injury with long healing times and significant scarring. In rare cases of systemic loxoscelism, serious intravascular, nephrological and/or multi-organ damage can occur, sometimes resulting in death. However, also of concern is that loxoscelism is diagnosed by medical personnel or presumed by the general public in highly improbable scenarios preventing or delaying proper remedy, which can lead to deleterious outcome. Herein, *Loxosceles* spider biology and medical aspects are reviewed. In particular, an extensive discussion of the distribution of the brown recluse spider, *L. reclusa* Gertsch & Mulaik 1940, is presented along with life history characteristics, which relate to the medical aspects of the genus. Also presented are manifestations and epidemiology of loxoscelism, misdiagnoses of bites by the medical community, alternative diagnoses confused with recluse spider bites and a discussion of the psychological basis for the proliferation of the myth of loxoscelism by both the general public and the medical community. North and South American species are reviewed because this is where the genus predominates and is the region where the most pertinent research has originated.

Keywords: Arachnida, brown recluse spider, dermonecrosis, distribution

There are very few spiders that are well known outside of the arachnological community. Almost all are large and conspicuous (tarantulas, orb weavers), medically important (black widows, Australian funnel web spiders) or medically implicated (hobo spiders). The spiders of the genus *Loxosceles* are ubiquitously infamous throughout the world because of their ability to occasionally cause significant skin necrosis also known as cutaneous loxoscelism.

Loxosceles spiders were not documented in the literature as medically important until the mid-20th century; previously, they were simply typical brown spiders that evoked little concern. In North America, once they were determined to be a public health threat, there was great interest in defining the distribution of the brown recluse spider, *L. reclusa* Gertsch & Mulaik 1940. This was followed by many reports of bites, verified and unverified, in both the medical and popular literature. Unfortunately, there was a parallel accompaniment of misinformation regarding the spider's distribution and its culpability as the etiology of skin lesions. Many advances have been made in medical areas in determining the treatment for loxoscelism, epidemiology of envenomations and the physiological mechanism of dermonecrosis. However, despite the infamy of the brown recluse spider, there was a surprising paucity of biological life history and distribution information after the initial efforts in the 1960s. In recent years, the genus has experienced more attention in biology and toxicology issues, particularly much excellent work by South American researchers with their native species.

The genus is known by the common names of violin, fiddleback, and recluse spiders in North America because of the darkly pigmented pattern on the anterior carapace (Fig. 1) and, in South America, by the rather non-specific name of

brown spiders. Frequently, the term *brown recluse spider* is colloquially used for any *Loxosceles* specimen, especially in North America. The brown recluse spider actually refers specifically to one species, *L. reclusa*; here, the genus will be referred to as recluse spiders.

The typical reviews of *Loxosceles* spiders written by medical authors adequately cover the medical aspects of venomous insult to humans but are often understandably deficient in regard to the biology of this rather unique group of spiders. The goal of this review is to provide a biological summary as it relates to the medical aspects of *Loxosceles* spiders for a medical audience but also to assimilate new medical information that would be of value to the arachnological community. Although emphasis will be on the North American *Loxosceles* spiders, in particular *L. reclusa*, information is presented for other *Loxosceles* species found worldwide when relevant.

TAXONOMY

Heineken and Lowe erected the genus *Loxosceles* for *L. citigrada* (now *rufescens*) from Madeira, Spain (Lowe 1835) although Dufour previously named the species as *Scytodes rufescens* in 1820. The name *Loxosceles* means *slanted legs* due to the way the spider holds its legs at rest (Cameron 2005) (Fig. 2) and is pronounced similar to *isosceles* as in the triangle of equal legs. The genus was originally placed in the family Sicariidae by Simon and has bounced around to the Scytodidae and Loxoscelidae. It was transferred back to the family Sicariidae based on spinneret morphology (Platnick et al. 1991) where it currently resides. The Sicariidae are currently comprised of spiders only from the genera *Loxosceles* (100 species) and *Sicarius* (21 species) (Platnick 2007).



Figure 1.—Brown recluse spider, *Loxosceles reclusa* Gertsch & Mulaik.

They are ecribellate, haplogyne spiders that are rather primitive as is evident by the simplistic genitalia, which makes differentiation among the many species somewhat challenging.

Much of the *Loxosceles* taxonomic activity occurred from 1958 through 1983, in the publication of the revisions by Gertsch (1958, 1967), Gertsch & Ennik (1983) and several of Gertsch's cave spider publications. Of the 100 *Loxosceles* species, 51 are native to North and Central America, 33 to South America with one (*L. rufipes* [Lucas 1834]) shared between the two continents. Gertsch named 70 of the 85 species that are native to the Western Hemisphere. Before

Gertsch & Mulaik described *L. reclusa* in 1940, European or South American names were used for the North American fauna. Therefore, one finds a 1929 record of a *L. refescens* [sic] bite in Kansas for a probable *L. reclusa* specimen (Schmaus 1929) and the South American name, *L. unicolor* Keyserling 1887, used for the southwestern American desert dweller, *L. deserta* Gertsch 1973. Gertsch & Mulaik considered the genus name to be masculine and, hence, the brown recluse was initially described as *L. reclusus* (and is sometimes occasionally incorrectly referenced as such in medical journals); later, the species name was changed to the feminine form of *L. reclusa*. The genus name *Loxosceles* is ambiguous as to its gender but was meant to be feminine as used initially by Heinecken & Lowe (Lowe 1835).

DISTRIBUTION

Given the reputation of the brown recluse, it is quite surprising that the distribution information for this spider is so sporadic and poorly documented from state to state. The information that is presented here is a compilation of more than a decade's effort to ferret out the limits of brown recluse distribution in North America. This section will focus mainly on the distribution of *L. reclusa* in North America, as this is the species of greatest concern on the continent. Because *Loxosceles* spiders are synanthropic (i.e., its population increases in association with humans), the actual extent of its native range cannot be readily determined.

The most comprehensive source for North America *Loxosceles* distribution information is the genus revision of Gertsch & Ennik (1983). Their distribution map consists of dots representing collections of *L. reclusa* in North America. As such, a dot in New York may signify one itinerant, transported specimen found in a hotel while a map dot for a location in Kansas represents thousands to millions of *L. reclusa* in a widespread area where populations are consistent,



Figure 2.—Male *Loxosceles laeta* (Nicolet) showing the slanted leg position when resting. Note the palpal femora and tibia, which are exceptionally long compared to North American *Loxosceles* species.

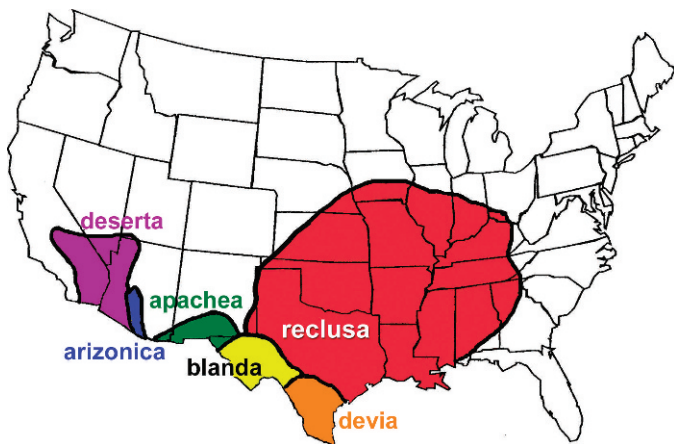


Figure 3.—Map of the distribution of the six *Loxosceles* species with widespread distribution in North America. Populations of *L. reclusa* in the middle of its range are commonly encountered, abundant in number, and reliable in their existence. As one reaches the margins of the distribution, *Loxosceles* spiders become less common and are more difficult to find. The other five species live in areas of the United States with sparse human population so their distribution is less reliable.

reliably found and spiders plentiful. Unfortunately, this non-specificity has been misinterpreted by non-arachnologists who overestimate *Loxosceles* distribution by considering the transported itinerants to define the boundaries of *Loxosceles* distribution. In addition, there are some areas on the map (e.g., the Texas Panhandle) where few collections are known. This could represent a valid scarcity of the spiders or sparse human population with few potential collectors or merely undersampling due to the spider's perceived commonness or some combination of the three factors. Nonetheless, if aware of obvious outliers, the map in Gertsch & Ennik (1983) is an accurate presentation of *L. reclusa* presence in North America. An additional study, which offered to identify any arachnid in the United States thought to be a recluse spider (Vetter 2005), corroborated the distribution as shown in Gertsch & Ennik (1983). However, both of these studies worked on the coarse-grained level of national distribution.

Information is presented below on a state-by-state basis for states on the periphery of *L. reclusa* distribution where populations diminish to non-existence. In the central area of the range (i.e., Arkansas, Missouri), it appears that entire states are infested although no actual publications are known to me that document the brown recluse spider in those states probably due to its ubiquity. The information for all the other states has been gathered from a wide and disparate number of sources including species lists by county, unpublished state maps, minor and arcane publications from state academies of science, agricultural experiment station bulletins, local and non-reviewed museum pamphlets, all corroborated with personal communications with arachnologists, entomologists, public and environmental health officials, poison control centers, and other authorities who might have decades-long oral history information. This is obviously a very mixed bag of resources; however, it is the best that could be assembled given the paucity of published information on such a well-known arachnid.

Starting in the northwestern corner of the *L. reclusa* distribution (Fig. 3), the spider is found in the southeastern corner of Nebraska (Rapp 1980); this information appears rather reliable considering the fine-grained listing by county for species in the state. For Iowa, the only sources known to me are a short publication (Stoaks 1980) and an unpublished map showing a few finds from the middle to southern portion of the state. Rapp (1980) mentions that Nebraska collections were only made in buildings, not in natural settings and Stoaks (1980) mentions the rarity of the spider in central Iowa, both statements of which would be consistent with the diminished density of an organism at the edge of its range. In Illinois, *L. reclusa* is common in the southern two-thirds of the state and found very rarely and unpredictably in the northern portion (north of Peoria) (Cramer & Mayright 2008). A similar story unfolds for Indiana with Indianapolis being about the northern limits. In Ohio, the brown recluse is rare (Oehler 1974; Bradley 2004) being found very sporadically and almost exclusively in the southwestern areas around Cincinnati to Dayton. In Kentucky, *L. reclusa* is common in the western region, decreasing in the central portions and is difficult to document in the eastern areas as one rises up into the Appalachian Mountains. Likewise, brown recluse spiders occur throughout Tennessee except in the extreme eastern counties, being very common in the western counties (Reed 1968; Vail & Watson 2002). There are scattered, isolated records of *Loxosceles* spiders in Virginia and North Carolina, which is indicative of the localized, spot-infestation establishment of transported specimens beyond the natural range of the spider. Similarly in South Carolina, the rarity of *Loxosceles* spiders has caused Frithsen et al. (2007) to posit that *L. reclusa* is non-native there. It is not common and restricted almost exclusively to the northwestern Piedmont geological province of Georgia (Vetter et al. unpubl. data), making this probably the only Atlantic coast state within the actual range of *L. reclusa*. Because of an interesting development, Louisiana, Mississippi, and Alabama will be discussed in the next paragraph. The brown recluse is very common throughout an extensive portion of Texas with other species (*L. devia* Gertsch & Mulaik 1940, *L. blanda* Gertsch & Ennik 1983, *L. apachea* Gertsch & Ennik 1983) replacing it further south and west (Fig. 3). Likewise, *L. reclusa* is extremely abundant in central to eastern Oklahoma and Kansas, however, there are no state publications known to me detailing this distribution. As the brown recluse is not native to Colorado (Vetter et al. 2003), the range terminates somewhere east of the Colorado border.

For Louisiana, Mississippi and Alabama, there are inconsistencies between the published Cooperative Economic Insect Report map of Gorham (1968) and other sources of information. Gorham (1968) shades every county in Mississippi indicating that brown recluses are found throughout the state. Neighboring states (Louisiana and Alabama) show only sporadic parishes or counties, respectively, as having recluses, mostly in the northern half of each state. Correspondence with R. Gorham in 2006 questioned the basis for the 1968 distribution in Mississippi. Simply, one phone call to the University of Mississippi resulted in the Biology chairman stating recluses were found in every county (R. Gorham, pers. comm.). This is no doubt based on the work of Dorris (1967)

who makes this same statement although examination of her field notes (copies provided by Pat Miller) and museum specimens indicates a very incomplete picture. The map of Gorham (1968) then became the basis for the inclusion of the entire Gulf coast area in recent maps in Vetter (2000), Swanson & Vetter (2005) and many publications citing these works. Because of discrepancies, studies are currently underway to systematically examine the distribution of the brown recluse spider in Mississippi, Alabama and Louisiana. Preliminary data indicate an absence or dearth of *L. reclusa* in the coastal region of the Gulf Coast states, similar to Georgia. Corroborating this, a Texas entomologist communicated that in 25 years, he has had only one brown recluse submitted from the Houston area and to collect significant number of specimens one must travel about 150 km inland (J. Tucker, pers. comm.).

Of the other American *Loxosceles* species, only the five shown in Fig. 3 have significant widespread distributions. However, because these distributions are in the southwestern desert where human population is sparse, these species could have greater range than currently known. Another aspect that limits our knowledge is a behavioral difference: because *L. reclusa* is a synanthropic spider, it is an urban pest, is abundant in homes and, therefore, is frequently collected by non-arachnologists. In contrast, the southwestern *Loxosceles* species appear to be much less adapted to human environments and, in domestic situations, are only found in homes that are surrounded by native vegetation. For example, although *L. deserta* is found around Phoenix, AZ and Las Vegas, NV, it is not an urban pest in areas where office buildings, hotels, casinos, and green lawns have arisen in the desert environment. Because *L. reclusa* is a synanthrope, lives where human population density is comparatively greater and has a larger distribution, it is involved in more encounters with humans than other North American species.

Of the medically important *Loxosceles* species in South America, *L. laeta* (Nicolet 1849) has the greatest distribution, being found in Brazil, Uruguay, Argentina, Chile, Peru, and Ecuador (Gertsch 1967). Others include *L. intermedia* Mello-Leitão 1934 (Brazil, Argentina) and *L. gaucho* Gertsch 1967 (southern Brazil) (Gertsch 1967). From South Africa, *L. parrami* Newlands 1981 was reported as medically important (Newlands et al. 1982).

The Mediterranean recluse, *L. rufescens* (Dufour 1820), is a worldwide tramp, originating from the circum-Mediterranean region. It has been collected in many localities in the United States (e.g., Boston, MA; New York City, NY; Philadelphia, PA; Harrisburg, PA; Reading, PA; Washington DC; Ann Arbor, MI; Indianapolis, IN; Knoxville, TN; Jacksonville, FL; Baton Rouge, LA; several localities in Ohio and Georgia; Las Animas, CO; Los Angeles and Fresno, CA; Spokane, WA [Gertsch & Ennik 1983; Vetter unpubl. data]). In nonendemic *Loxosceles* areas in North America, it is more likely to find a spot infestation of the non-native *L. rufescens* than the native *L. reclusa*. The Mediterranean recluse has also become established in Australia (Southcott 1976). Gertsch (1967) states that there are no valid specimens of *L. rufescens* from South America. While others have described this species as cosmopolitan, Gertsch (1967) states that this is a misnomer. Although *L. rufescens* exists in many localities, in non-endemic

areas it is typically found only indoors and in highly circumscribed distribution, heavily infesting one building or several if interconnected by conduits.

LIFE HISTORY AND BIOLOGY RELEVANT TO MEDICAL ISSUES

After *Loxosceles* spiders became a medical entity, they were the subjects of biological and medical articles as researchers rushed to provide information on this new public health threat. Below is a review of the biological traits as they relate to the features that do or do not show a potential as a public health concern.

Longevity, fecundity and resistance to starvation.—*Loxosceles* spiders have long life spans compared to many seasonal entelegynes, which pass through a life cycle in < 1 yr. Hite et al. (1966) provide a longevity for *L. reclusa* of 1.5 yr for males and 1.7 yr for females with a maximum of 2.5 yr for one female when animals were maintained in the lab. They mention that life spans would probably have been longer had they been subjected to winter temperatures. Indeed, Horner & Stewart (1967) maintained their animals in winter refuges to provide a more natural scenario; their spiders survived over 5 seasons (spiders were still alive at the time of publication). Elzinga (1977) reports average life spans for *L. reclusa* males (897 da) and females (794 da) with 25% of the females living over 1,000 da, including one surviving 4.8 yr. Lowrie (1980) reared *L. laeta* under sporadic feeding conditions (initially weekly, then once every 3 to 10 mo, then starved to death); these spiders took an average of 2.1 yr to mature and lived another 4.8 yr as adults. Similarly, Fischer & Vasconcellos-Neto (2005a) report longevities of 1176 ± 478 da for *L. intermedia* females and 557 ± 87 da for males. However, these quantities are for captive animals confined to vials, not exposed to detrimental environmental factors, and, hence, might grossly overestimate the life span in natural or synanthropic settings.

Compared to many other common spiders, which produce hundreds to thousands of eggs per egg sac or over a lifetime, *Loxosceles* spiders have a more modest fecundity. Female *L. reclusa* average 50 eggs per egg sac (range 0 to 91, $n = 146$), and 2.7 egg sacs per female with a 48% hatch rate ($n = 55$) (Hite et al. 1966). For laboratory-reared *L. intermedia* restricted to one mating, egg sacs contained approximately 30 eggs where 70% hatched, however, the egg sacs of field-collected females of unknown mating history averaged around 50 eggs with 80% hatch (Fischer & Vasconcellos-Neto 2005b). When kept without access to additional matings, female *L. reclusa* (Horner & Stewart 1967) and lab-reared, singularly-mated *L. intermedia* females (Fischer & Vasconcellos-Neto 2005b) experience a decrease in fecundity per sac and/or egg viability with successive egg sacs throughout a season. For *L. reclusa* from figure 5 of Horner & Stewart (1967), from the 1st to 3rd egg sac, there is a drop in egg number per sac from about 27 to 18 and decrease of hatch rate from 66% to 37%. Field-collected *L. intermedia* females of unknown mating history did not show this decline (Fischer & Vasconcellos-Neto 2005b). Similar fecundity numbers are presented for other species: *L. laeta* – mean of 88.4 eggs per sac (range 22 to 138, $n = 81$) (Galiano 1967), *L. gaucho* – mean of 61.3 eggs per sac (range 25 to 117, $n = 78$) (Rinaldi et al. 1997) and *L.*

hirsuta Mello-Leitão 1931—mean of 33.7 eggs per sac with 93% hatch ($n = 113$) (Fischer & da Silva 2001).

Loxosceles are well known for surviving long periods of time without food. This is no doubt due in part to a slow metabolism; compared to similar-sized spiders, *L. reclusa* spiders have a low heart rate on the level of theraphosids (Carrel & Heathcote 1976). Eskafi et al. (1977) purposely starved field-collected *L. reclusa* at different temperatures and relative humidities. Spiders at 5° C survived 4 to 7 mo whereas this dropped to 1 to 2 mo at 30° C and less than 2 wk at 40° C. Lowrie (1980) starved mature *L. laeta*, which took an average of 1.2 yr to succumb.

Dispersal capability.—Recluse spiders do not have a great propensity for dispersal on their own accord. Ballooning is a well-known dispersal mechanism for small spiders, typically as early instars, allowing them to transport themselves miles from their take-off point, carried on uplifting air currents. However, recluse spiders are haplogynes; haplogynes do not balloon (Beatty 1970). In the infestation of *L. laeta* in southern California in the 1960s, although spiders were indeed found in many buildings, razing of an infested building eliminated the population, which did not reinfest the new building constructed on the site (Waldron 1969).

Tolerance of conspecifics and population size in human structures.—*Loxosceles* spiders can be found in very high density in synanthropic situations. A Kansas family collected 2,055 *L. reclusa* spiders in their home in 6 mo (Vetter & Barger 2002) and a survey in Kansas showed that 22 of 25 homes had *L. reclusa* with an average of 83.5 ± 114.9 spiders per home (range 1 to 526) (Sandidge 2004). In a Chilean survey, 29% of the homes were infested with *L. laeta* spiders with the five highest-infested rural homes averaging 163 ± 56 specimens (Schenone et al. 1970). In an Oklahoma barn, a team of arachnologists collected 1,150 brown recluses in three consecutive nights with little diminishing of the numbers although the size of the spiders decreased slightly as the collection progressed (C. Shillington, pers. comm.). Recluses are not social spiders in the sense of sharing webs, prey capture and defense such as *Metepeira* and other social or cooperative spiders (Uetz & Hieber 1997) but rather there is species-recognition that either reduces aggressive interactions and/or allows escape to a safe distance to avoid predation such as exists for *L. gaucho* in female-female (Stropa & Rinaldi 2001) and male-male interactions (Stropa 2007). Dozens of *Loxosceles* spiderlings of the same species can be reared in close quarters in a single jar with minimal cannibalism as long as there is adequate prey to eat and crevices in which to hide (Vetter & Rust 2008).

Heat and cold tolerance.—The upper and lower limits for temperature tolerance appear unremarkable. Hite et al. (1966) report that the activity limits of *L. reclusa* are 4.5° to 43° C. With 4-h exposures, there was 47% mortality for *L. reclusa* at -7° C and -10° C; with 30-da exposure all spiders survived at 0° C but none at -5° C (Cramer & Mayright 2008). With 1-h exposures at constant temperatures, Fischer & Vasconcellos-Neto (2003) report an upper LT₅₀ (lethal temperatures for 50% of subjects) for *L. intermedia* (35° C) and *L. laeta* (32° C); the lower LT₅₀ was -7° C for both species.

Hunting behavior and hiding places.—*Loxosceles* spiders are active hunters that do not make webs for prey capture in the

typical spider sense. They will extend lines of silk from a retreat to opportunistically alert them to the presence of entangled prey. Although recluse spiders are cribellates, their silk is dry and shares several characteristics of cribellate silk (Knight & Vollrath 2002); hence, prey capture is via entanglement not adhesion.

Loxosceles spiders are reclusive as their name implies and have a predilection for crevices and other tight locations. In nature, *Loxosceles* spiders can be found under rocks and the loose bark of dead trees. In synanthropic environments, recluse spiders are found in cardboard boxes especially under folded flaps, in cupboards, behind bookcases and dressers, in trash, under broken concrete and asphalt and, of medical concern, in shoes and clothes left out on the floor or stored in closets and garages. In South America, *Loxosceles* spiders are known by the common names of *araña de detrás de los cuadros* (spider behind the picture) and *araña de los rincones* (spider in the corner) (Schenone et al. 1970). There is a propensity for *L. laeta* and *L. intermedia* to be found frequently in association with rough surfaces such as cardboard, construction material, wood and cloth and less so with smooth surfaces such as metal and ceramic (Fischer & Vasconcellos-Neto 2005c). Additionally, Fischer & Vasconcellos-Neto (2005c) remark that these spiders are almost absent from natural areas immediately surrounding the infested buildings where they were collected.

Summary of *Loxosceles* life history characters as they relate to public health.—Considering the biological information above, *Loxosceles* spiders present a mixed complement of characteristics that would both encourage and discourage their importance as a public health threat. The aspects of long life, resistance to starvation and propensity to seek refuge in cardboard boxes would translate into a spider that could be well adapted to survival during accidental transport by humans allowing proliferation of a viable breeding population in a new area. However, this point is an overused bromide frequently espoused in the medical literature regarding the detrimental potential for *Loxosceles* dispersal throughout North America. Rarely do these authors provide corroborative evidence that this actually happens (Vetter & Bush 2002a). Although recluse spiders obviously can be found outside their endemic range, they still are quite rare and are not nearly as common as perceived by the medical community and general public (Vetter 2005).

Loxosceles spider fecundity is in the lower part of the spectrum compared to several spiders but definitely would cluster with other hunting spiders of similar size (J.F. Anderson 1990) so there is nothing remarkable about this life history characteristic. However, one aspect that reduces the potential for *Loxosceles* establishment outside endemic areas is that egg number and fecundity diminishes with successive egg sacs when re-mating is prevented. This is most likely explained by the difference of haplogyne and entelegyne reproductive biology. With entelegynes, the first male to mate fertilizes the majority of eggs and female spiders can store viable sperm for months (Elgar 1998). For example, the entelegyne western black widow spider, *Latrodectus hesperus* Chamberlin & Ivie 1935 produced 10+ egg sacs in captivity over a period of a year without re-mating, with many having > 300 eggs per sac and fertility reaching around 80 to 90% for the last egg sacs (Kaston 1970). In contrast, the haplogyne

recluses with last male sperm priority may require matings between egg sacs to maintain fertility. Therefore, unless a transported *Loxosceles* female has recently mated, her potential for producing viable egg sacs with high hatch rate is low.

Because of their inability to balloon, *Loxosceles* spiders are not well adapted to disperse from an infestation point. In non-endemic areas, they may develop large populations within one structure but they will not easily spread from that focal point as have many non-native, invasive entelegynes, which have established themselves over large portions of North America. In this respect, *Loxosceles* spiders are almost reliant upon humans for transport over large distances. Therefore, despite the dire concerns of some personal communications from the lay public to the author regarding the spread of *Loxosceles* spiders due to global warming, this does not appear to be a likely issue of immediate concern.

Loxosceles spiders develop large populations in synanthropic environments in endemic areas; if an infestation exists, multiple specimens of *Loxosceles* spiders should be available for collection. Therefore, outside of nonendemic *Loxosceles* areas, the finding of a single recluse specimen should be treated as a spot infestation of one, transported immigrant and, when preserved in alcohol, the threat of loxoscelism (and its typical requisite hyperbole and overreaction) should be a moot point. In northern climates, spiders would readily survive indoors but will perish outside with low winter temperatures. However, in structures infested with recluse spiders, precautions can minimize the probability of envenomation (i.e., clean up clutter, move beds away from the wall, remove bed skirts or ruffles, do not use the underside of the bed for storage, shake out clothes and shoes before dressing).

MEDICAL ASPECTS OF LOXOSCELISM

The first North American associations of spiders with necrotic skin lesions occurred in the 19th century in Texas (Caveness 1872; Wilson 1893) then later in Kansas (Schmaus 1929). In South America, there were many circumstantial associations of skin lesions and *Loxosceles* spiders in the early part of the 20th century (Macchiavello 1947). In 1947, this association was proven in South America (Macchiavello 1947); in North America, this was confirmed a decade later (Atkins et al. 1957). After that, an explosion of reports spread the word about the newly implicated *Loxosceles* spiders as dermonecrotic agents.

The ability of *Loxosceles* spiders to cause significant skin injury has been and will continue to be reviewed extensively in the medical literature. Because this topic is more than well covered in medical and toxicology journals, only a brief review will be presented here; interested readers are encouraged to seek out da Silva et al. (2004), Hogan et al. (2004), Swanson & Vetter (2005, 2006), Wasserman & Lowry (2005), Pauli et al. (2006). Patel et al. (1994) and Wasserman & Lowry (2005) review the underlying physiological mechanisms of dermonecrosis. Pauli et al. (2006) review the many controversial aspects of *Loxosceles* antivenom application and present an extensive data-rich epidemiological comparison among studies.

There are four categories of *Loxosceles* bites:

- Unremarkable (very little damage, self-healing)

- Mild reaction (redness, itching, slight lesion but typically self-healing)
- Dermonecrotic (necrotic skin lesion considered by many the typical reaction)
- Systemic or viscerocutaneous (affect vascular system, very rare, potentially fatal)

One point that should be kept in mind is that most *Loxosceles* bites do not result in serious skin lesions, are typically self-healing without medical intervention and do not result in scarring; regular supportive care is typically sufficient with excellent outcome (Wright et al. 1997; Anderson 1998; Cacy & Mold 1999). Of patients developing necrotic lesions, about two-thirds heal without complications (Pauli et al. 2006). The more extreme manifestations of venom injury generate concern and publication of medical reports and, hence, skew the perception of the severity of the average loxoscelism event. Nonetheless, in the most severe manifestations, loxoscelism lesions can grow to 40 cm in size, healing can take several months and leave a disfiguring scar. Cutaneous loxoscelism damage is greater in obese victims (e.g., Masters 1998) because the venom enzymes readily destroy poorly vascularized adipose tissue. There can be gravitational spread of the lesion. Rare systemic manifestations can be serious and potentially life threatening (especially in children). Typically, *Loxosceles* spiders bite for defensive purposes and the resulting injury is a single focal lesion. Bites frequently occur when the spider is compressed against exposed flesh, typically while a person is sleeping or getting dressed.

Most of the following paragraph is summarized from Wasserman & Lowry (2005) and comments made by Wasserman in reviewing this manuscript. In dermonecrotic lesions, *Loxosceles* venom causes an immediate vascular constriction at the bite site. Within 3 hours, polymorphonuclear leukocytes infiltrate the envenomation site. At 6 hours, dermal edema initiates. Itching develops along with inflammation and ischemia (local and temporary blood supply deficiency due to obstruction) at the bite site, which becomes painful and tender to the touch. For bites that become significant, there may be a characteristic bleb or blister, varying from flesh-colored to purple/black. Within a few hours to days, an eschar (hardened ulcer) may form, which eventually sloughs off, exposing soft tissue, which may take several months to heal. Within the first days, there also may be a characteristic bull's-eye lesion (blue center at the bite surrounded by a white ring of reduced blood circulation surrounded by a red ring of erythematous tissue although sometimes may exhibit more purplish hues or a necrotic center). Physicians consider this a classic sign of cutaneous loxoscelism but this also occurs in Lyme borreliosis (Osterhoudt et al. 2002) so hasty diagnosis in Lyme disease prevalent areas should be of concern. There is no current clinically available bioassay for loxoscelism detection (da Silva et al. 2004) although an experimental bioassay does exist (Gomez et al. 2002).

Necrosis is caused by a rare enzyme, sphingomyelinase D (SMD), ranging in molecular weight from 32 to 35 kDA depending upon the species and is found only in spiders (*Loxosceles*, *Sicarius*) and a few pathogenic bacteria (e.g., *Corynebacteria*) (Binford et al. 2005). It has been present in all *Loxosceles* spiders tested so far (Binford & Wells 2003). In *L.*

intermedia, SMD is absent in eggs and 1st and 2nd instar spiderlings, is first detectable in 3rd instars and increases in quantity as the spiders increase in size (Andrade et al. 1999). Of experimental interest, one must be careful in extrapolating from the response of test animals to that of humans. *Loxosceles* venom causes dermonecrosis in humans, rabbits, and guinea pigs but not rats or mice (da Silva et al. 2004). Compared to humans, rabbits heal faster and do not develop chronic necrosis (Pauli et al. 2006). Recent research suggests that instead of one compound, the dermonecrotic factors may be a family of different toxin isoforms working synergistically (Ribeiro et al. 2007).

In rare systemic reactions (<1% of the cases of suspected *L. reclusa* bites [Anderson 1998] with higher incidence in South American loxoscelism), recluse venom may cause events such as hemolysis, disseminated intravascular coagulation (i.e., mini-clots throughout the vascular system) and sepsis, which can lead to serious injury and possibly death (Wasserman et al. 1999; Wasserman & Lowry 2005). Hemolysis is mediated by disruption of red blood cell membranes by SMD leading to free hemoglobin in the blood and the passing of dark urine; rhabdomyolysis from local tissue damage may also contribute to renal failure (Hogan et al. 2004). There is evidence for direct nephrotoxicity of *Loxosceles* venom components (Chaim et al. 2006). Renal damage typically is exhibited in small children. Anderson (1998) remarked, however, that with supportive hydration and dialysis, outcome was excellent.

Treatment for loxoscelism is controversial. Many remedies such as the anti-leprosy drug dapsone, hyperbaric oxygen, nitroglycerin patches, and even electroshock therapy have been proffered as effective cutaneous loxoscelism treatments (Swanson & Vetter 2005). However, the lack of a control group in all of these studies in concert with the self-healing nature of many loxoscelism lesions and the use of presumptive loxoscelism victims who may have had non-arachnid etiologies precludes definitive assessment of efficacy. Additionally, dapsone has detrimental side effects (Hogan et al. 2004; Swanson & Vetter 2005) and has recently been shown to be ineffective for experimental dermal loxoscelism (Elston et al. 2005). A common recommendation for most non-necrotic loxoscelism lesions is simple RICE (rest, ice, compression, elevation) therapy although alternate therapy recommends a relaxed neutral position instead of elevation and cool compresses instead of ice, the latter of which may cause its own detrimental effects. In the 1960s, early excision of damaged tissue was routinely advocated but now is only recommended for severely necrotic lesions and then, not until the borders of the wound have ceased spreading and are well defined; early excision can lead to delayed wound healing, increased infection, worsened scarring and disability (Anderson 1998; Wasserman & Lowry 2005). Also, with pyoderma gangrenosum, a condition sometimes misdiagnosed as cutaneous loxoscelism, removal of tissue increases injury via pathergy (Chow & Ho 1996); therefore, improper debridement in this case could be highly detrimental. In North America, antibiotics are often given to prevent secondary infection from the patient's endogenous bacterial fauna; recluse bites are generally aseptic for the first few days post-bite (Wasserman & Lowry 2005). In South America, antibiotics are not routinely given because secondary infection is uncommon; antivenom is

frequently used to counter loxoscelism although its efficacy is controversial (Pauli et al. 2006). Antivenom is not commercially available in North America (Hogan et al. 2004). Some authors have argued that antivenom is most effective during the first 24 hour post-bite but most patients do not seek treatment until after the first day as the wound worsens. Nonetheless, Pauli et al. (2006) report that there is benefit to using it up to 72 h in that dermonecrosis may still develop but lesion size is smaller and healing time shorter. Barbaro et al. (2005) show high cross-reactivity among five *Loxosceles* venoms (three South American and two North American species) indicating the potential for a single global *Loxosceles* antivenom. A recent novel avenue of therapy involves topical application of tetracycline which reduced the progression of lesion formation in rabbits whereas oral administration was ineffective (Paixão-Cavalante et al. 2007); further research will be necessary to determine if this has therapeutic utility for envenomations in humans.

Wright et al. (1997) present information on 111 Tennessee patients with verified and presumed brown recluse spider bites; of these, 37% exhibited necrotic lesions and 2.7% required grafting. Cacy & Mold (1999) report the results of an Oklahoma physician survey with 149 presumptive loxoscelism patients; 40% exhibiting necrosis, 13% resulting in scarring and the average lesion healed in 2 wk. Sams et al. (2001) present 19 verified *L. reclusa* envenomations where 11 patients developed necrotic lesions (6 of which were larger than 1 cm²) but none developed a chronic non-healing lesion. Eight, five and six patients had mild, moderate and severe lesions, respectively, with average healing times of 8, 22 and 74 da, respectively. No deaths were reported in these three studies.

In South America, Málague et al. (2002) describe a Brazilian study of 359 presumptive and verified cases of loxoscelism with 53% of patients developing necrosis, 4% healed with scarring, 4% developed systemic loxoscelism and no deaths. Of the spiders brought in by patients that could be identified, most were *L. gaucho* with a few *L. laeta*. In Chile, Schenone et al. (1989) describe results of 216 loxoscelism events: 34 patients developed systemic loxoscelism with eight dying. The spider involved in Chile was *L. laeta*, considered to have the most virulent bite of known recluse spiders (Wasserman & Lowry 2005); this may be due, in part, to it being the largest of all *Loxosceles* spiders.

Of other species, in the southwestern American deserts, *L. deserta* has been involved in verified envenomations with effect (Russell et al. 1969). In Israel, *L. rufescens* was blamed for an outbreak of skin lesions in orchard workers (Borkan et al. 1995) although association was mostly presumptive and some cases of persons with multiple episodes of lesions seem somewhat suspect as valid loxoscelism.

Yet the risk of a *Loxosceles* spider bite is small even in heavily infested structures. Schenone et al. (1970) mentions collecting 5,449 *L. laeta* from 645 Chilean homes and "no cases of loxoscelism were registered." Similarly, in the Kansas home where 2,055 *L. reclusa* were collected in 6 mo, no one in the family of four had sustained a perceptible loxoscelism event in the 6 years of occupancy at the time of the study (Vetter & Barger 2002). However, at the 11-yr mark, the mother was bitten on the finger while reaching into laundry and shook a brown recluse from a shirt sleeve; the finger

turned red and swelled slightly but healed without incident (D. Barger, pers. comm.).

OVERDIAGNOSIS OF SPIDER BITES

In North America, once the brown recluse spider became known as a spider of medical importance, the medical aspects were vigorously researched and reported. In the 1960s, case histories appeared in medical journals and new county and state records were documented in the USDA's weekly Cooperative Economic Insect Report as the brown recluse spider became well known outside of the arachnological community. Reports of brown recluse spider bites were common in the local media and in national magazines. As much as *Loxosceles* spiders are a legitimate public health threat, of equal concern is the overdiagnosis of loxoscelism as a common etiology for skin lesions.

Over the decades, the diagnoses of cutaneous loxoscelism became commonplace in the North American medical community. Although the majority of the reports emanated from endemic *Loxosceles* regions such as Tennessee and Oklahoma (Wright et al. 1997; Cacy & Mold 1999), additional reports of alleged bites (without evidence of a *Loxosceles* spider) were made in places such as Montana (Lee et al. 1969), Colorado (Mara & Myers 1977) and Canada (several references in Bennett & Vetter 2004). The belief of the existence of *Loxosceles* spiders as legitimate and common causes of dermonecrotic lesions was widespread and became deeply entrenched in the medical community, which diagnosed bites, the media which reported this unique and sound-bite friendly health threat, and the general public who readily believed both entities as trusted sources of knowledge. In contrast, then and now, arachnologists in non-endemic *Loxosceles* areas familiar with the local spider fauna and who were aware that *Loxosceles* spiders were either completely absent or extremely rare, tried to correct these misconceptions, but were often met with vehement resistance and unequivocal disbelief.

In the 1980s, Dr. Phillip Anderson (University of Missouri dermatologist specializing in loxoscelism treatment) and Dr. Findlay Russell (southern California physician, medical toxicologist, and one of the world's foremost authorities on animal venoms and plant toxins) attempted to alert the medical community to the errors of their ways in regard to jumping so vigorously on the brown recluse spider bite bandwagon (Anderson 1982; Russell & Gertsch 1983; Russell 1986). Russell & Gertsch (1983) state that of approximately 600 cases seen by them, 80% of the alleged spider bite cases were caused by other arthropods or other disease states. Russell (1986) further stated that 60% of his loxoscelism consultations emanated from areas lacking *Loxosceles* spiders. Other authors also chimed in (e.g., Kunkel 1985); however, by and large, this message was forgotten or trampled under as medical personnel continued to rely heavily on *Loxosceles* spiders as common etiologies to explain idiopathic lesions (i.e., lesions with unknown causative agents). This message was left idle until the early 21st century when editorials (e.g., Vetter 2000; Vetter & Bush 2002a,b; Bennett & Vetter 2004) and the research papers mentioned below were produced to counter the *Loxosceles* misinformation.

Because it is impossible to prove a negative (i.e., that no *Loxosceles* spiders live in the area), a different tack was taken.

The belief in the ubiquity of *Loxosceles* spiders in an area was based almost solely on the number of incidents of skin lesions attributed to *Loxosceles* spiders. Therefore, a contradictory argument was presented: if the great number of skin lesions in a specific geographic area were truly caused by *Loxosceles* spiders, then the spiders should be readily collected and verified in the area, both historically and contemporaneously. Using as much taxonomic information as was available (museum and personal arachnological collections, correspondence with municipal agencies that receive spiders for identification [e.g., state diagnostic clinics, departments of public and environmental health, department of food and agriculture]) and comparing it to the number of alleged incidents of *Loxosceles* envenomation (e.g., published report or tallies of physician loxoscelism diagnoses, poison control center data bases, physician questionnaire responses), in nonendemic *Loxosceles* regions of North America, the number of loxoscelism diagnoses always outnumbered the verified number of *Loxosceles* spiders for such areas as Colorado and the Pacific coast states (Vetter et al. 2003), Florida (Vetter et al. 2004), Canada (Bennett & Vetter 2004), South Carolina (Frithsen et al. 2007) and Pennsylvania (Vetter et al. unpubl. data). The South Carolina paper was rather spectacular as it was based on two physician questionnaires in 1990 and 2004 where over 1,200 loxoscelism diagnoses were reported by primary care physicians in just those 2 years for the state which had, historically, only 6 disjunct localities producing a total of 45 *Loxosceles* spiders. When one considers that in endemic areas one can find great quantities of *Loxosceles* spiders in homes (Schenone et al. 1970; Vetter & Barger 2002; Sandidge 2004), mostly without loxoscelism in any occupant, it should be obvious that much misdiagnosis is occurring. These 1,216 diagnoses also represented a fraction of the actual number of South Carolina loxoscelism diagnoses because the survey response rate was only 42% in 1990 and 19% in 2004 and did not include dermatologists or emergency room physicians. These papers have been instrumental in helping to overturn the dogged resistance that the entrenched myths surrounding loxoscelism create, causing other dermonecrotic agents, which are far more likely, to be considered.

MISDIAGNOSES BY PHYSICIANS AND A LIST OF DIFFERENTIAL DIAGNOSES

Unfortunately, in the early years as well as now, physicians published unconfirmed bite cases, which confused and erroneously inflated the body of loxoscelism symptomology by reporting manifestations from a raft of non-arachnid medical conditions. Loxoscelism dermatologist Philip Anderson stated, "Because the well-accepted rules of evidence have been ignored, a large part of the total clinical literature on loxoscelism is invalid" (P. C. Anderson 1990). It has been suggested that editors require authors to distinguish between proven and presumptive loxoscelism reports in order to provide a more accurate basis for the information in the medical literature (such as found in de Souza et al. 2008) and that loxoscelism diagnoses without proof of an envenoming spider are best restricted to endemic *Loxosceles* regions (Anderson 1982; Vetter & Bush 2002a,b, 2004). Laack et al. (2007) provides a notable exception by documenting a verified bite by a *Loxosceles* spider transported to Minnesota.

Table 1.—A list of medical conditions that have been or could be misdiagnosed as cutaneous loxoscelism. Modified from Swanson & Vetter (2005).

Infections
Atypical mycobacteria
Bacterial
- <i>Streptococcus</i>
- <i>Staphylococcus</i> (especially MRSA)
- Lyme borreliosis
- Cutaneous anthrax
- Syphilis
- Gonococemia
- Rickettsial disease
- Tularemia
Deep Fungal
- Sporotrichosis
- Aspergillosis
- Cryptococcosis
Ecthyma gangrenosum (<i>Pseudomonas aeruginosa</i>)
Parasitic (Leishmaniasis)
Viral (herpes simplex, herpes zoster (shingles))
Vascular occlusive or venous disease
Antiphospholipid-antibody syndrome
Livedoid vasculopathy
Small-vessel occlusive arterial disease
Venous stasis ulcer
Necrotising vasculitis
Leukocytoclastic vasculitis
Polyarteritis nodosa
Takayasu's arteritis
Wegeners granulomatosis
Neoplastic disease
Leukemia cutis
Lymphoma (e.g., mycosis fungoides)
Primary skin neoplasms (basal cell carcinoma, malignant melanoma, squamous cell carcinoma)
Lymphomatoid papulosis
Topical and Exogenous Causes
Burns (chemical, thermal)
Toxic plant dermatitis (poison ivy, poison oak)
Factitious injury (i.e., self-induced)
Pressure ulcers (i.e., bed sores)
Other arthropod bites
Radiotherapy
Other Conditions
Calcific uremic arteriolopathy
Cryoglobulinemia
Diabetic ulcer
Langerhans'-cell histiocytosis
Pemphigus vegetans
Pyoderma gangrenosum
Septic embolism

There are many medical maladies that manifest in necrotic skin lesions but, unfortunately, the well-known deleterious effect of cutaneous loxoscelism causes this condition to be diagnosed far more often than it should. Russell & Gertsch (1983) initiated a list of dermonecrotic etiologies, which were or could be mistaken for cutaneous loxoscelism; additional authors are still adding to this list (Table 1). Some of the reported misdiagnoses include Lyme borreliosis (Osterhoudt et al. 2002), chemical burn (Vetter & Bush 2002c), anthrax (Roche et al. 2001), and *Staphylococcus* infection (Dominguez 2004).

One of the most important developments in medical arachnology in the last decade is the emergence of a bacterial infection (methicillin-resistant *Staphylococcus aureus* [MRSA]) as a major etiology of skin and soft tissue injury and the recognition of this infection as a frequent misdiagnosis for spider bite in general (Dominguez 2004; Miller & Spellberg 2004; Moran et al. 2006; Vetter et al. 2006; Cohen 2007) and brown recluse bite in particular (Dominguez 2004). This confusion is caused in part because the general public, who lack sufficient experience to accurately assess their injuries, use "spider bite" as the common explanation for idiopathic skin lesions (Miller & Spellberg 2004); of 248 patients who had MRSA, 29% presented to physicians with complaint of spider bites (Moran et al. 2006). MRSA awareness is receiving broad dissemination as it is reported routinely in the general media. It is a bacterial infection, which has developed genetic resistance to many broad-spectrum antibiotics. It is considered originally of nosocomial origin (i.e., from hospitals) and, due to its exposure to many antibiotics, it is quite pernicious. Common risk factors among patients with MRSA include histories of hospitalization or surgery or long-term care residence (Klevens et al. 2007). Another strain, community-acquired MRSA (CA-MRSA), manifests in people who do not have exposure to hospital settings but is common where people are housed in high density for long periods of time such as in prisons, nursing homes, long-term health care facilities, collegiate and professional sports locker rooms, and military barracks (Dominguez 2004; Vetter et al. 2006; Cohen 2007). MRSA is resistant to β -lactam antibiotics such as oral cephalexin; currently, MRSA is treated with antibiotics such as bactrim (trimethoprim-sulfamethoxazole), rifampin, doxycycline, and clindamycin (Benoit & Suchard 2006; Moran et al. 2006). CA-MRSA is susceptible to a larger range of antibiotics than nosocomial MRSA, possibly because the former has had less exposure to a wide spectrum of antibiotics. Reports of annual American death rate from invasive MRSA are estimated at 18,000+ per year (Klevens et al. 2007), which, if true, would exceed the annual death rate from AIDS virus (Bancroft 2007).

The continued awareness and education regarding MRSA and CA-MRSA has allowed for better health care as physicians are now correctly medicating a potentially deadly bacterial infection instead of treating alleged spider bites. Arachnologists who are aware of the communal epidemiological conditions that breed and spread CA-MRSA have contradicted medical personnel and correctly assessed alleged spider bite events as MRSA episodes, which allowed for proper remedy (Vetter et al. 2006; G.B. Edwards, pers. comm.). Epidemiological evidence that would suggest MRSA and would contraindicate spider involvement include 1) multiple contemporaneous lesions on one person, 2) sequential lesions on one person over time, and 3) multiple persons with lesions who live together or are in close contact (Vetter et al. 2006). Although Fagan et al. (2003) claim MRSA infection secondary to spider bites as a common association (with no case of definitive spider involvement), this faulty MRSA-spider bite connection has been summarily criticized (Miller & Spellberg 2004; Cohen 2007). Additionally, a study screening for MRSA in randomly-collected house spiders in Chicago showed no evidence of the bacterium on spider body parts

(Baxtrom et al. 2006) further supporting the lack of spider origin for a condition well established as a nosocomial infection.

HUMAN PSYCHOLOGY AND THE PROLIFERATION OF LOXOSCELISM DIAGNOSES

A large part of the basis for awareness of *Loxosceles* spiders throughout North American society is due to the dramatic, psychological nature surrounding the diagnosis of loxoscelism. Although the comments made here are more pertinent for nonendemic *Loxosceles* areas, there will be some relevance for endemic areas as well. The diagnosis of loxoscelism involves the psychology of both the patient with a lesion and the physician making the diagnosis along with the interaction of the physician-patient relationship. Much of the information here has been developed over the last decade via conversations and correspondences with medical colleagues, exposure to hundreds of emails from concerned North Americans attempting to discover the cause of their mysterious skin lesions as well as studies or treatises that delve into myth proliferation and the psychology of the cognitive medical diagnostic process. The points presented below are by no means exhaustive.

From the patient standpoint, there are many aspects that cause loxoscelism to retain a high profile in the general public's eye.

- Adverse reaction to spiders in western civilization ranges from mild dislike to intense arachnophobia (Isbister 2004). Entities perceived in a negative light are readily blamed as culprits for people's maladies and misfortunes despite the reality of the involvement (Difonzo & Bordia 2006); spiders qualify well as scapegoats. Physicians who likewise suffer from arachnophobia or spider disgust will be predisposed to inappropriately blame spiders as idiopathic skin lesion etiologies (Isbister 2004).
- Spiders are commonly encountered, readily recognizable organisms; therefore, they are embraced as causes of medical ills (Isbister 2004). It is difficult for most members of the non-medical world to visualize or conceptualize *Staphylococcus* or pyoderma gangrenosum.
- Patients appear to prefer accepting an exogenous cause rather than an endogenous response for a medical affliction (Benoit & Suchard 2006). Blaming a spider over which there is no control is more agreeable than admitting that some inherent physical weakness or detrimental life style choice is causing the illness.
- "Spider bite" is an oddly comforting diagnosis for patients with skin lesions (Benoit & Suchard 2006). It becomes a badge of courage that they "survived" an encounter with a beast of perceived danger. People who feel they have suffered loxoscelism recount their stories for years, which are then retold by others (Vetter, unpubl. data); this is one of the mechanisms for reinforcing myths in the general public (Difonzo & Bordia 2006). In contrast, one rarely recounts to friends and colleagues a personal bout with a bacterial infection, especially long after the incident.
- Patients often put blind faith in their physicians (Vetter, unpubl. data). If a physician diagnoses a brown recluse spider bite, this carries far more weight in the patient's eyes as to the probability of *Loxosceles* spiders in a local area

than does the lifelong collecting experience of regional arachnologists (Vetter & Isbister 2008). Physicians knowingly work in an environment with accepted uncertainty (Montgomery 2006); however, patients feel that physicians work in a world of absolute knowledge.

For the physician, there are many aspects that maintain the persistence of loxoscelism as an etiology of idiopathic skin lesions.

- Patients understandably visit a physician because they seek answers for their illnesses. The physician wants to provide an answer because that is his/her job and, hence, this drives the desire for a diagnosis. There is an approximate overall 15% misdiagnosis rate in medicine (Elstein 1995). Although medicine is described as an art and a science, Montgomery (2006) advocates repeatedly that it should be considered neither but, rather, "a rational, science-using practice."
- Physicians may be reluctant to request the necessary tests to determine if a bacterial or viral agent might be the cause of a skin lesion (Isbister 2004; Benoit & Suchard 2006). This is caused in part by physicians not sufficiently pursuing the causative agent (Benoit & Suchard 2006) but also the desire to keep costs low in an era of spiraling medical expenses.
- Medical schools used to instruct their students that loxoscelism is a common cause of necrotic skin lesions. Colleagues have relayed that these lessons included truisms such as "if it is a necrotic wound, it is a brown recluse bite" and that brown recluse bites were "deadly" despite the rarity of such dire outcome. This appears to be changing as the medical textbooks are incorporating recent research (in particular, the distribution map of Swanson & Vetter [2005]) along with greater awareness of the differential diagnoses for dermonecrosis especially in regard to MRSA.
- The most common cause of cognitive error resulting in misdiagnosis is premature closure where, once a diagnosis is made, a physician fails to consider other likely differential diagnoses (Kuhn 2002; Graber et al. 2005). Senior physicians are just as likely to commit this error as junior physicians (Kuhn 2002). These mistakes arise as a manifestation of the heuristic diagnostic process, which when done correctly, results in the desired effects of reducing delay, cost and anxiety (Redelmeier 2005). Other cognitive errors, such as confirmational bias, prevent physicians from considering alternative diagnoses (Groopman 2007). Again, loxoscelism is a dramatic diagnosis and, once considered, a physician may lock on to this etiology to the exclusion of more probable causative agents.
- There is conflict in the medical field regarding improbable diagnoses (Montgomery 2006). The conservative-minded axiom of "when you hear hoof beats, think horses, not zebras" reinforces the need to first consider common etiologies with which a patient might present and, more importantly, the uncommon manifestation of a common etiology. The more dramatic zebra diagnoses are recalled more easily due to their novelty (Kuhn 2002) and, hence, are diagnosed too frequently. Nonetheless, even when knowingly faced with an improbable diagnosis of once-in-a-career probability, the physician does not want to overlook this rare condition out of professional duty to the patient (Montgomery 2006). Hence, the dynamic nature

of loxoscelism causes medical personnel to diagnose (and publish articles) where the evidential threads to *Loxosceles* spiders are extremely flimsy and sometimes obviously wrong (Anderson 1982; Vetter & Swanson 2007).

- Spider bites are prematurely embraced as etiologies for dermonecrosis without proper evidence-based medicine. This phenomenon is well demonstrated by an Australian episode with white-tailed spiders, *Lampona cylindrata* (L. Koch 1866) and *L. murina* L. Koch 1873 (Lamponidae) with speculation that they caused necrotic arachnidism (Sutherland 1983). This led to a spate of publications documenting alleged effects of white-tailed spider bite based on presumptive diagnosis without spider involvement (Isbister & Gray 2003; White 2003; Isbister 2004). Verified bites with minor manifestation were brushed aside as aberrant; calls for funding to develop antivenom were made (White 2003). After 20 years of spider incrimination, Isbister & Gray (2003) definitively demonstrated with 130 verified *Lampona* bites with only minor, non-necrotic manifestation, that these spiders were not probable causes of necrotic arachnidism. Parallel features exist for loxoscelism in North America and blaming of dermonecrosis on wolf spiders in South America (Isbister 2004; Vetter & Isbister 2008).

CONCLUDING STATEMENT

The medical arachnological world encompassing *Loxosceles* spiders is an intriguing mixture of arachnology, toxicology, medicine, psychology, mythology, and even journalism. Without a doubt, *Loxosceles* spiders present a real envenomation threat for many regions of the world from a shy, reclusive spider. However, the exaggeration of this threat has given this genus a reputation that greatly extends past its actual physical presence. There are many facets to tease out of this situation as *Loxosceles* spiders' infamy has garnered concern outside the academic world. The facets are subject to human psychology and the checkered ability of non-scientists to properly interpret scientific data especially for a subject like loxoscelism, which lends itself so readily to exaggeration and myth. Although new research is providing the answers to the physiological mechanisms and treatment of the valid threat of loxoscelism, there is room for additional research in areas as simple as accurate distribution for states on the border of the currently known range of recluse spiders. *Loxosceles* spiders will continue to generate significant attention in the worlds of arachnology and medicine as well as interest and concern from the general public.

ACKNOWLEDGMENTS

I thank the dozens of arachnologists and entomologists who have corresponded with me over the last 15 years in regard to *Loxosceles* distribution in their state, province, or country as well as those curators who loaned their museum's *Loxosceles* collection for examination. Thanks also are expressed to the many physicians around the United States who have become close colleagues in building a two-way conduit between arachnology and medicine, providing answers to many questions about the underpinnings of the physiology of envenomation injury and the psychology of medical diagnoses and, conversely, for taking the opportunity to ask many questions about spiders and their role in envenomations. Pat

Miller (Northwest Mississippi Community College) graciously provided photocopies of the pertinent sections of Peggy Rae Dorris's dissertation and information regarding Dorris's field notebook for which I am grateful. The manuscript was improved by comments by Paula E. Cushing, G.B. Edwards, Gail Stratton, Gary Wasserman, and two anonymous reviewers. Finally, I would like to dedicate this paper to a dear friend and cherished arachnological colleague, H. Don Cameron, who took me under his avuncular wing at the 1993 AAS meeting in Seattle and has witnessed the development of my *Loxosceles* research program from its inception.

LITERATURE CITED

- Anderson, J.F. 1990. The size of spider eggs and estimates of their energy content. *Journal of Arachnology* 18:73–78.
- Anderson, P.C. 1982. Letter to the editor. *Toxicon* 20:533.
- Anderson, P.C. 1990. Loxoscelism and the history of the Missouri brown spider: a recollection of Dr. Joseph Flynn. *Missouri Medicine* 87:747–752.
- Anderson, P.C. 1998. Missouri brown recluse spider: a review and update. *Missouri Medicine* 95:318–322.
- Andrade, R.M.G., K.C. Oliveira, A.L. Giusti, W.D. Silva & D. Tambourgi. 1999. Ontogenetic development of *Loxosceles intermedia* spider venom. *Toxicon* 37:627–632.
- Atkins, J.A., C.W. Wingo & W.A. Sodeman. 1957. Probable cause of necrotic spider bite in the Midwest. *Science* 126:73.
- Bancroft, E.A. 2007. Antimicrobial resistance: it's not just for hospitals. *Journal of the American Medical Association* 298:1803–1804.
- Barbaro, K.C., I. Knysak, R. Martins, C. Hogan & K. Winkel. 2005. Enzymatic characterization, antigenic cross-reactivity and neutralization of dermonecrotic activity of five *Loxosceles* spider venoms of medical importance in the Americas. *Toxicon* 45:489–499.
- Baxtrom, C., T. Mongkolpradit, J.N. Kasimos, L.M. Braune, R.D. Wise, P. Sierwald & K.R. Ramsey. 2006. Common house spiders are not likely vectors of community-acquired methicillin-resistant *Staphylococcus aureus* infections. *Journal of Medical Entomology* 43:962–965.
- Beatty, J. 1970. The spider genus *Ariadna* in the Americas (Araneae: Dysderidae). *Bulletin of the Museum of Comparative Zoology* 139:433–517.
- Bennett, R.G. & R.S. Vetter. 2004. An approach to spider bites: erroneous attribution of dermonecrotic lesions to brown recluse or hobo spider bites in Canada. *Canadian Family Physician* 50:1098–1101.
- Benoit, R. & J.R. Suchard. 2006. Necrotic skin lesions: spider bite – or something else? *Consultant* 46:1386–1394.
- Binford, G.J. & M.A. Wells. 2003. The phylogenetic distribution of sphingomyelinase D activity in venoms of haplogyne spiders. *Comparative Biochemistry and Physiology B* 135:25–33.
- Binford, G.J., M.H.J. Cordes & M.A. Wells. 2005. Sphingomyelinase D from venoms of *Loxosceles* spiders: evolutionary insights from cDNA sequences and gene structure. *Toxicon* 45:547–560.
- Borkan, J., E. Gross, Y. Lubin & I. Oryan. 1995. An outbreak of venomous spider bites in a citrus grove. *American Journal of Tropical Medicine and Hygiene* 52:228–230.
- Bradley, R.A. 2004. In Ohio's Backyard: Spiders. *Ohio Biological Survey Backyard Series #4*. 183 pp.
- Cacy, J. & J.W. Mold. 1999. The clinical characteristics of brown recluse spider bites treated by family physicians: an OKPRN study. *Journal of Family Practice* 48:536–542.
- Cameron, H.D. 2005. An etymological dictionary of North American spider genus names. Pp. 274–330. In *Spiders of North America: an Identification Manual*. (D. Ubick, P. Paquin, P.E. Cushing & V. Roth, eds.). American Arachnological Society.

- Carrel, J.E. & R.D. Heathcote. 1976. Heart rate in spiders: influence of body size and foraging energetics. *Science* 193:148–150.
- Caveness, W.A. 1872. Insect bite, complicated with fever. *Nashville Journal of Medicine and Surgery* 10:333–337.
- Chaim, O.M., Y.B. Sade, R.B. da Silveira, L. Toma, E. Kalapothakis, C. Chávez-Olortegui, O.C. Mangili, W. Gremski, C.P. von Dietrich, H.B. Nader & S.S. Veiga. 2006. Brown spider dermonecrotic toxin directly induces nephrotoxicity. *Toxicology and Applied Pharmacology* 211:64–77.
- Chow, R.K.P. & V.C. Ho. 1996. Treatment of pyoderma gangrenosum. *Journal of the American Academy of Dermatology* 34:1047–1060.
- Cohen, P.R. 2007. Community-acquired methicillin-resistant *Staphylococcus aureus* skin infections: a review of epidemiology, clinical features, management and prevention. *International Journal of Dermatology* 46:1–11.
- Cramer, K.L. & A.V. Mayright. 2008. Cold temperature tolerance and distribution of the brown recluse spider *Loxosceles reclusa* (Araneae, Sicariidae) in Illinois. *Journal of Arachnology* 36:136–139.
- da Silva, P.H., R.B. da Silveira, M.H. Appel, O.C. Mangili, W. Gremski & S.S. Veiga. 2004. Brown spiders and loxoscelism. *Toxicon* 44:693–709.
- de Souza, A.L., C.M. Malaque, J. Sztanjbok, C.C. Romano, A.J. Duarte & A.C. Seguro. 2008. *Loxosceles* venom-induced cytokine activation, hemolysis, and acute kidney injury. *Toxicon* 51:151–156.
- Difonzo, N. & P. Bordia. 2006. *Rumor Psychology: Social and Organizational Approaches*. American Psychological Association, Washington, DC. 292 pp.
- Dominguez, T.J. 2004. It's not a spider bite, it's community-acquired methicillin-resistant *Staphylococcus aureus*. *Journal of the American Board of Family Practice* 17:220–26.
- Dorris, P.R. 1967. The spiders of Mississippi. Ph.D. dissertation. University of Mississippi, Oxford. 283 pp.
- Elgar, M.A. 1998. Sperm competition and sexual selection in spiders and other arachnids. Pp. 307–339. *In* Sperm Competition and Sexual Selection. (T.R. Birkhead & A.P. Møller, eds.). Academic Press, San Diego, California.
- Elstein, A.S. 1995. Clinical reasoning in medicine. Pp. 49–59. *In* Clinical Reasoning in the Health Professions. (J. Higgs & M. Jones, eds.). Butterworth-Heinemann Ltd., Oxford, UK.
- Elston, D.M., S.D. Miller, R.J. Young III, J. Eggers, D. McGlasson, W.H. Schmidt & A. Bush. 2005. Comparison of colchicine, dapsone, triamcinolone, and diphenhydramine therapy for the treatment of brown recluse spider envenomation: a double-blind, controlled study in a rabbit model. *Archives of Dermatology* 141:595–597.
- Elzinga, R.J. 1977. Observations on the longevity of the brown recluse spider, *Loxosceles reclusa* Gertsch & Mulaik. *Journal of the Kansas Entomological Society* 50:187–188.
- Eskafi, F.M., J.L. Frazier, R.R. Hocking & B.R. Norment. 1977. Influence of environmental factors on longevity of the brown recluse spider. *Journal of Medical Entomology* 14:221–228.
- Fagan, S.P., D.H. Berger, K. Rahwan & S.S. Awad. 2003. Spider bites presenting with methicillin-resistant *Staphylococcus aureus* infection require early aggressive treatment. *Surgical Infections* 4:311–315.
- Fischer, M.L. & E.M. da Silva. 2001. Oviposição e desenvolvimento de *Loxosceles hirsuta* Mello-Leitão, 1931 (Araneae; Sicariidae). *Estudos de Biologia Curitiba* 47:15–20.
- Fischer, M.L. & J. Vasconcellos-Neto. 2003. Determination of the maximum and minimum lethal temperatures (LT₅₀) for *Loxosceles intermedia* Mello-Leitão, 1934 and *L. laeta* (Nicolet, 1849) (Araneae, Sicariidae). *Journal of Thermal Biology* 28:563–570.
- Fischer, M.L. & J. Vasconcellos-Neto. 2005a. Development and life tables of *Loxosceles intermedia* Mello-Leitão 1934 (Araneae, Sicariidae). *Journal of Arachnology* 33:758–766.
- Fischer, M.L. & J. Vasconcellos-Neto. 2005b. Parameters affecting fecundity of *Loxosceles intermedia* Mello-Leitão 1934 (Araneae, Sicariidae). *Journal of Arachnology* 33:670–680.
- Fischer, M.L. & J. Vasconcellos-Neto. 2005c. Microhabitats occupied by *Loxosceles intermedia* and *Loxosceles laeta* (Araneae: Sicariidae) in Curitiba, Paraná, Brazil. *Journal of Medical Entomology* 42:756–765.
- Frithsen, I.L., R.S. Vetter & I.C. Stocks. 2007. Reports of envenomation by brown recluse spiders exceed verified specimens of *Loxosceles* spiders in South Carolina. *Journal of the American Board of Family Medicine* 20:483–488.
- Galiano, M.E. 1967. Ciclo biológico y desarrollo de *Loxosceles laeta* (Nicolet, 1849) (Araneae, Scytodidae). *Acta Zoologica Lilloana* 23:431–464.
- Gertsch, W.J. 1958. The spider genus *Loxosceles* in North America, Central America, and the West Indies. *American Museum Novitates* 1907:1–46.
- Gertsch, W.J. 1967. The spider genus *Loxosceles* in South America (Araneae, Scytodidae). *Bulletin of the American Museum of Natural History* 136:117–174.
- Gertsch, W.J. & F. Ennik. 1983. The spider genus *Loxosceles* in North America, Central America, and the West Indies (Araneae, Loxoscelidae). *Bulletin of the American Museum of Natural History* 175:264–360.
- Gomez, H.F., D.M. Krywko & W.V. Stoecker. 2002. A new assay for the detection of *Loxosceles* species (brown recluse) spider venom. *Annals of Emergency Medicine* 39:469–474.
- Gorham, J.R. 1968. The geographic distribution of the brown recluse spider, *Loxosceles reclusa* (Araneae, Scytodidae) and related species in the United States. *United States Department of Agriculture Cooperative Economic Insect Report* 18:171–175.
- Graber, M.L., N. Franklin & R. Gordon. 2005. Diagnostic error in internal medicine. *Archives of Internal Medicine* 165:1493–1499.
- Groopman, J. 2007. *How Doctors Think*. Houghton Mifflin Co., Boston, Massachusetts. 307 pp.
- Hite, J.M., W.J. Gladney, J.L. Lancaster & W.H. Whitcomb. 1966. The biology of the brown recluse spider. University of Arkansas, Fayetteville. *Agricultural Experiment Station Bulletin* No. 711. 26 pp.
- Hogan, C.J., K.C. Barbaro & K. Winkel. 2004. Loxoscelism: old obstacles, new directions. *Annals of Emergency Medicine* 44:608–624.
- Horner, N.V. & K.W. Stewart. 1967. Life history of the brown spider, *Loxosceles reclusa* Gertsch and Mulaik. *Texas Journal of Science* 19:334–347.
- Isbister, G.K. 2004. Necrotic arachnidism: the myth of a modern plague. *Lancet* 364:549–553.
- Isbister, G.K. & M.R. Gray. 2003. White-tail spider bite: a prospective study of 130 definite bites by *Lampona* species. *Medical Journal of Australia* 179:199–202.
- Kaston, B.J. 1970. Comparative biology of American black widow spiders. *Transactions of the San Diego Society of Natural History* 16:33–82.
- Klevens, R.M., M.A. Morrison, J. Nadle, S. Petit, K. Gershman, S. Ray, L.H. Harrison, R. Lynfield, G. Dumyati, J.M. Townes, A.S. Craig, E.R. Zell, G.E. Fosheim, L.K. McDougal, R.B. Carey & S.K. Fridkin. 2007. Invasive methicillin-resistant *Staphylococcus aureus* infections in the United States. *Journal of the American Medical Association* 298:1763–1771.
- Knight, D.P. & F. Vollrath. 2002. Spinning an elastic ribbon of spider silk. *Philosophical Transactions of the Royal Society of London B* 357:219–227.
- Kuhn, G.J. 2002. Diagnostic errors. *Academic Emergency Medicine* 9:740–750.

- Kunkel, D.B. 1985. The myth of the brown recluse spider. *Emergency Medicine* 17(5):124–128.
- Laack, T.A., L.G. Stead & M.E. Wolfe. 2007. Images in emergency medicine. *Annals of Emergency Medicine* 50:368.
- Lee, R.V., R.S. Buker Jr. & K.M. Petersen. 1969. North American loxoscelism: two presumptive cases from northern Montana. *Rocky Mountain Medical Journal* 66:57–59.
- Lowe, R.T. 1835. Descriptions of two species of Araneidae, natives of Madeira. *Zoological Journal* 5:320–323.
- Lowrie, D.C. 1980. Starvation longevity of *Loxosceles laeta* (Nicolet) (Araneae). *Entomological News* 91:130–132.
- Macchiavello, A. 1947. Cutaneous arachnoidism or cutaneous spot of Chile. *Puerto Rico Public Health and Tropical Medicine* 22: 425–466.
- Málaque, C.M.S., J.E. Castro-Valencia, J.L.C. Cardoso, F.O.S. França, K.C. Barbaro & H.W. Fan. 2002. Clinical and epidemiological features of definitive and presumed loxoscelism in São Paulo, Brazil. *Revista Instituto de Medicina Tropical de São Paulo* 44:139–143.
- Mara, J.E. & B.S. Myers. 1977. Brown spider bite. *Rocky Mountain Medical Journal* 74:257–258.
- Masters, E.J. 1998. Loxoscelism. *New England Journal of Medicine* 339:379.
- Miller, L.G. & B. Spellberg. 2004. Spider bites and infections caused by community-associated methicillin-resistant *Staphylococcus aureus*. *Surgical Infections* 5:321–322.
- Montgomery, K. 2006. *How Doctors Think: Clinical Judgment and the Practice of Medicine*. Oxford University Press, Oxford, UK. 246 pp.
- Moran, G.J., A. Krishnadasan, R.J. Gorwitz, G.E. Fosheim, L.K. McDougal, R.B. Carey & D.A. Talan. 2006. Methicillin-resistant *S. aureus* infections among patients in emergency rooms. *New England Journal of Medicine* 355:666–674.
- Newlands, G., C. Isaacson & C. Martindale. 1982. Loxoscelism in the Transvaal, South Africa. *Transactions of the Royal Society of Tropical Medicine and Hygiene* 76:610–615.
- Oehler, C. 1974. The medical significance of spiders at Cincinnati, Ohio. *Cincinnati Museum of Natural History* 23(3):1–11.
- Osterhoudt, K.C., T. Zautis & J.J. Zorc. 2002. Lyme disease masquerading as brown recluse spider bite. *Annals of Emergency Medicine* 39:558–561.
- Paixão-Cavallante, D., C.W. van den Berg, R.M. Gonçalves-de-Andrade, M.F. Fernandes-Pedrosa, C.K. Okamoto & D.V. Tambourgi. 2007. Tetracycline protects against dermonecrosis induced by *Loxosceles* spider venom. *Journal of Investigative Dermatology* 127:1410–1418.
- Patel, K.D., V. Modur, G.A. Zimmerman, S.M. Prescott & T.M. McIntyre. 1994. The necrotic venom of the brown recluse spider induces dysregulated endothelial cell-dependent neutrophil activation. *Journal of Clinical Investigation* 94:631–642.
- Pauli, I., J. Puka, I.C. Gubert & J.C. Minozzo. 2006. The efficacy of antivenom in loxoscelism treatment. *Toxicon* 48:123–137.
- Platnick, N.I. 2007. *The World Spider Catalog, Version 8.0*. American Museum of Natural History. Online at <http://research.amnh.org/entomology/spiders/catalog/SICARIIDAE.html>
- Platnick, N.I., J.A. Coddington, R.R. Forster & C.E. Griswold. 1991. Spinneret morphology and the phylogeny of haplogyne spiders (Araneae, Araneomorphae). *American Museum Novitates* 3016:1–73.
- Rapp, W.F. 1980. A catalog of spiders of Nebraska. *Novitates Arthropodae* 1(2):1–39.
- Redelmeier, D.A. 2005. The cognitive psychology of missed diagnoses. *Annals of Internal Medicine* 142:115–120.
- Reed, H.B. Jr.. 1968. The brown recluse spider and loxoscelism in Tennessee. *Journal of the Tennessee Academy of Science* 43: 110–114.
- Ribeiro, R.O.S., O.M. Chaim, R.B. da Silveira, L.H. Gremski, Y.B. Sade, K.S. Paludo, A. Senff-Ribeiro, J. de Moura, C. Chávez-Olortegui, W. Gremski, H.B. Nader & S.S. Veiga. 2007. Biological and structural comparison of recombinant phospholipase D toxins from *Loxosceles intermedia* (brown spider venom). *Toxicon* 50:1162–1174.
- Rinaldi, I.M.P., L.C. Forti & A.A. Stropa. 1997. On the development of the brown spider *Loxosceles gaucho* Gertsch (Araneae, Sicariidae): the nympho-imaginal period. *Revista Brasileira de Zoologia* 14:697–706.
- Roche, K.J., M.W. Chang & H. Lazarus. 2001. Cutaneous anthrax infection. *New England Journal of Medicine* 345:1611.
- Russell, F.E. 1986. A confusion of spiders. *Emergency Medicine* 18(11):8–13.
- Russell, F.E. & W.J. Gertsch. 1983. Letter to the editor. *Toxicon* 21:337–339.
- Russell, F.E., W.G. Waldron & M.B. Madon. 1969. Bites by the brown spiders *Loxosceles unicolor* and *Loxosceles arizonica* in California and Arizona. *Toxicon* 7:109–112.
- Sams, H.H., S.B. Hearsh, L.L. Long, D.C. Wilson, D.H. Sanders & L.E. King Jr. 2001. Nineteen documented cases of *Loxosceles reclusa* envenomation. *Journal of the American Academy of Dermatology* 44:603–608.
- Sandridge, J. 2004. Predation by cosmopolitan spiders on the medically significant pest species *Loxosceles reclusa* (Araneae: Sicariidae): limited possibilities for biological control. *Journal of Economic Entomology* 97:230–234.
- Schenone, H., A. Rojas, H. Reyes, F. Villarroel & G. Suarez. 1970. Prevalence of *Loxosceles laeta* in houses in central Chile. *American Journal of Tropical Medicine and Hygiene* 19:564–567.
- Schenone, H., T. Saavedra, A. Rojas & F. Villarroel. 1989. Loxoscelismo en Chile. Estudios epidemiológicos, clínicos y experimentales. *Revista Instituto de Medicina Tropical de São Paulo* 31:403–415.
- Schmaus, L.F. 1929. Case of arachnoidism (spider bite). *Journal of the American Medical Association* 92:1265–1266.
- Southcott, R.V. 1976. Spiders of the genus *Loxosceles* in Australia. *Medical Journal of Australia* 1:406–408.
- Stoaks, R.D. 1980. Occurrence of the brown recluse spider (Araneae: Loxoscelidae) in Iowa. *Proceedings of the Iowa Academy of Science* 87:159.
- Stropa, A.A. 2007. Social encounters between male brown spiders, *Loxosceles gaucho* (Araneae, Sicariidae). *Journal of Arachnology* 35:493–498.
- Stropa, A.A. & I.M.P. Rinaldi. 2001. Relative tolerance and communication in agonistic behaviour between females of *Loxosceles gaucho* (Araneae, Sicariidae). *Bulletin of the British Arachnological Society* 12:41–45.
- Sutherland, S. 1983. Necrotic arachnidism: a possible new Australian syndrome. *Toxicon* 21(Supplement 3):435.
- Swanson, D.L. & R.S. Vetter. 2005. Bites of brown recluse spiders and suspected necrotic arachnidism. *New England Journal of Medicine* 352:700–707.
- Swanson, D.L. & R.S. Vetter. 2006. Loxoscelism. *Clinics in Dermatology* 24:213–221.
- Uetz, G.W. & C.S. Hieber. 1997. Colonial web-building spiders: balancing the costs and benefits of group-living. Pp. 458–475. *In* Social Behavior in Insects and Arachnids. (J.C. Choe & B.J. Crespi, eds.). Cambridge University Press, Cambridge, UK.
- Vail, K.M. & J.A. Watson. 2002. *The brown recluse spider*. University of Tennessee Agricultural Extension Service Bulletin PB1191. 16 pp.
- Vetter, R.S. 2000. Myth: idiopathic wounds are often due to brown recluse or other spider bites throughout the United States. *Western Journal of Medicine* 173:357–358.
- Vetter, R.S. 2005. Arachnids submitted as suspected brown recluse spiders (Araneae: Sicariidae): *Loxosceles* species are virtually restricted to their known distributions but are perceived to exist throughout the United States. *Journal of Medical Entomology* 42:512–521.

- Vetter, R.S. & D.K. Barger. 2002. An infestation of 2,055 brown recluse spiders (Araneae: Sicariidae) and no envenomations in a Kansas home: implications for bite diagnoses in nonendemic areas. *Journal of Medical Entomology* 39:948–951.
- Vetter, R.S. & S.P. Bush. 2002a. Reports of presumptive brown recluse spider bites reinforce improbable diagnosis in regions of North America where the spider is not endemic. *Clinical Infectious Diseases* 35:442–445.
- Vetter, R.S. & S.P. Bush. 2002b. The diagnosis of brown recluse spider bite is overused for dermonecrotic wounds of uncertain etiology. *Annals of Emergency Medicine* 39:544–546.
- Vetter, R.S. & S.P. Bush. 2002c. Chemical burn misdiagnosed as brown recluse spider bite. *American Journal of Emergency Medicine* 20:68–69.
- Vetter, R.S. & S.P. Bush. 2004. Additional considerations in presumptive brown recluse spider bites and dapsone therapy. *American Journal of Emergency Medicine* 22:494–495.
- Vetter, R.S., P.E. Cushing, R.L. Crawford & L.A. Royce. 2003. Diagnoses of brown recluse spider bites (loxoscelism) greatly outnumber actual verifications of the spider in four western American states. *Toxicon* 42:413–418.
- Vetter, R.S., G.B. Edwards & L.F. James. 2004. Reports of envenomation by brown recluse spiders (Araneae: Sicariidae) outnumber verifications of *Loxosceles* spiders in Florida. *Journal of Medical Entomology* 41:593–597.
- Vetter, R.S. & G.K. Isbister. 2008. Medical aspects of spider bites. *Annual Review of Entomology* 53:409–429.
- Vetter, R.S., B.B. Pagac, R.W. Reiland, D.T. Bolesh & D.L. Swanson. 2006. Skin lesions in barracks: consider community-acquired methicillin-resistant *Staphylococcus aureus* infection instead of spider bites. *Military Medicine* 171:830–832.
- Vetter, R.S. & M.K. Rust. 2008. Refugia preferences by the spiders *Loxosceles reclusa* and *Loxosceles laeta* (Araneae: Sicariidae). *Journal of Medical Entomology* 45:36–41.
- Vetter, R.S. & D.L. Swanson. 2007. Of spiders and zebras: publication of inadequately documented loxoscelism case reports. *Journal of the American Academy of Dermatology* 56:1063–1064.
- Waldron, W.G. 1969. *Loxosceles laeta* (Nicolet), an introduced species in Los Angeles County. *Bulletin of the Entomological Society of America* 15:377–379.
- Wasserman, G.S., R. Garola, J. Marshall & S. Gustafson. 1999. Death of a 7 year old by presumptive brown recluse spider bite. *Journal of Toxicology – Clinical Toxicology* 37:614–615.
- Wasserman, G.S. & J.A. Lowry. 2005. *Loxosceles* spiders. Pp. 1195–1203. *In* Critical Care Toxicology: Diagnosis and Management of the Critically Poisoned Patient. (J. Brent, K.L. Wallace, K.K. Burkhardt, S.D. Phillips & J.W. Donovan, eds.). Elsevier Mosby, Philadelphia, Pennsylvania.
- White, J. 2003. Debunking spider bite myths. *Medical Journal of Australia* 179:180–181.
- Wilson, J.T. 1893. Poisoning by the bite of the southern spider. *Transactions of the Southern Surgical and Gynecological Association* 5:406–411.
- Wright, S.W., K.D. Wrenn, L. Murray & D. Seger. 1997. Clinical presentation and outcome of brown recluse spider bite. *Annals of Emergency Medicine* 30:28–32.

Manuscript received 15 January 2008, revised 27 February 2008.